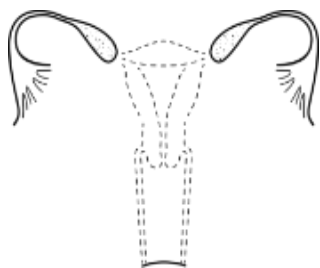




MÜLLERIAN AGENESIS

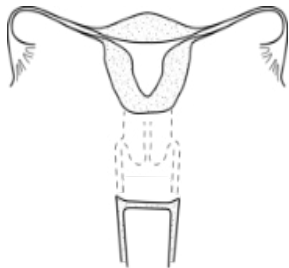


MÜLLERIAN AGENESIS

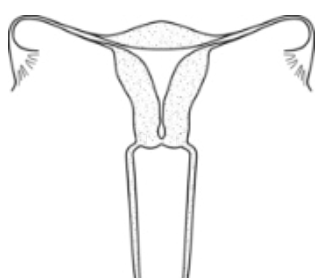


MÜLLERIAN AGENESIS WITH R/L ATROPHIC UTERINE REMNANT WITH FUNCTIONAL ENDOMETRIUM

CERVICAL AGENESIS

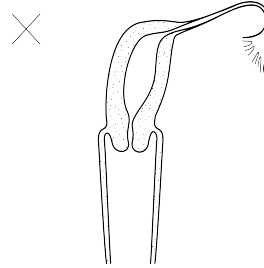


CERVICAL AGENESIS

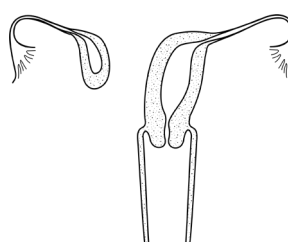


DISTAL CERVICAL AGENESIS

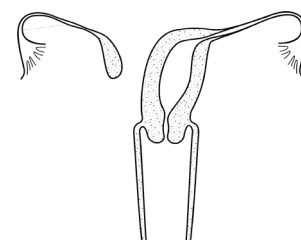
UNICORNUATE UTERUS



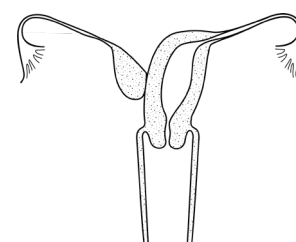
R/L UNICORNUATE UTERUS



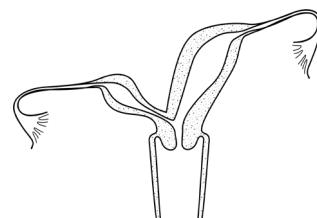
R/L UNICORNUATE WITH R/L DISTAL UTERINE REMNANT WITH FUNCTIONAL ENDOMETRIUM



R/L UNICORNUATE WITH R/L DISTAL ATROPHIC UTERINE REMNANT

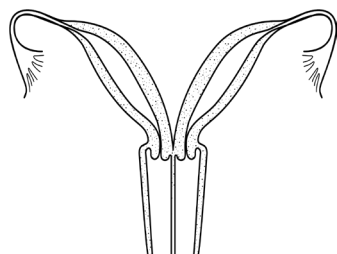


R/L UNICORNUATE WITH R/L ASSOCIATED ATROPHIC UTERINE REMNANT

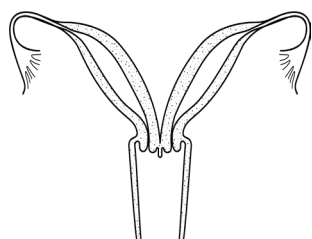


R/L UNICORNUATE WITH R/L UTERINE HORN COMMUNICATING AT LEVEL OF CERVIX

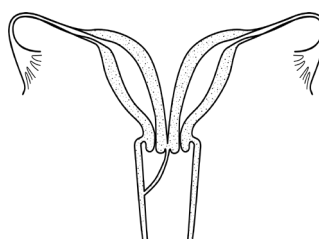
UTERUS DIDELPHYS



UTERUS DIDEPHYS AND LONGITUDINAL SEPTUM

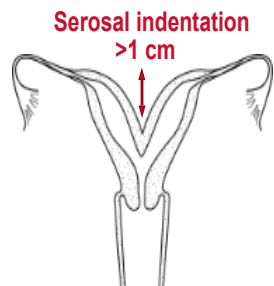


UTERUS DIDELPHYS AND +/- LONGITUDINAL VAGINAL SEPTUM OF VARIABLE LENGTH

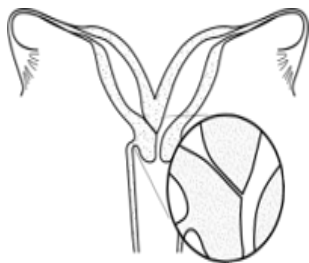


UTERUS DIDELPHYS AND OBSTRUCTED R/L HEMIVAGINA

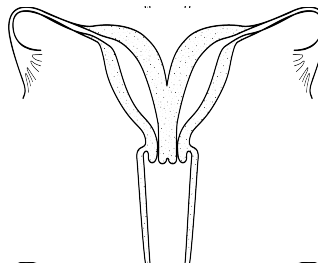
BICORNUATE UTERUS



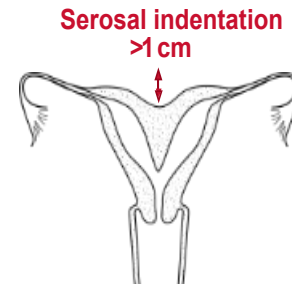
BICORNUATE UTERUS



BICORNUATE UTERUS WITH R/L COMMUNICATING TRACT



UTERUS BICORNUATE BICOLLIS

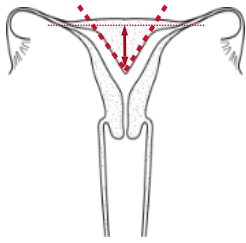


COMBINED BICORNUATE SEPTATE UTERUS

SEPTATE UTERUS

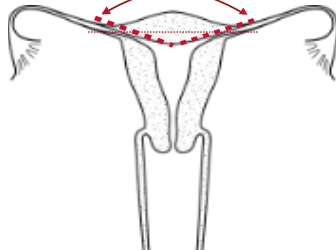
TRANSVERSE VAGINAL SEPTUM

Septum length >1 cm
Septum angle <90°

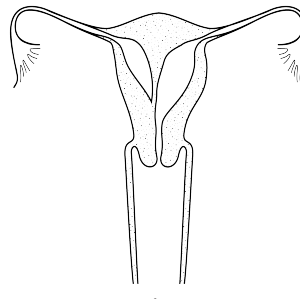


PARTIAL SEPTATE UTERUS

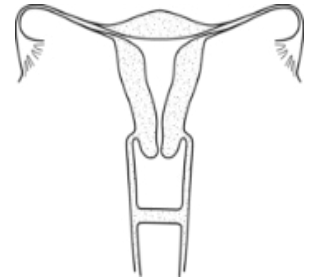
Arcuate/Normal length
≤1cm angle >90°



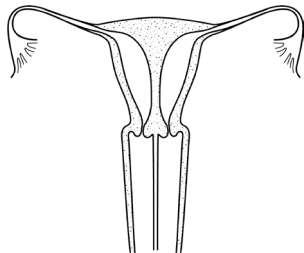
NORMAL/ARCULATE UTERUS



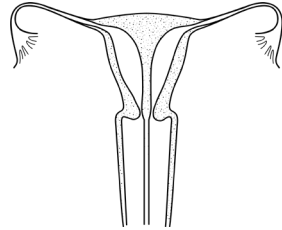
ROBERT'S UTERUS



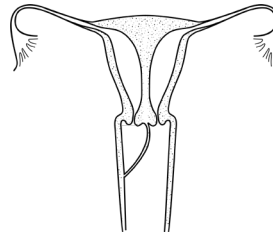
MID VAGINAL SEPTUM



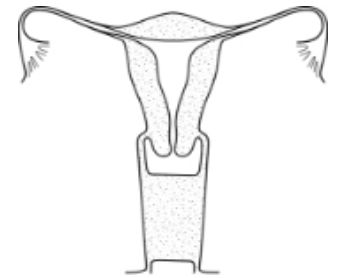
COMPLETE SEPTATE UTERUS WITH DUPLICATED CERVICES AND LONGITUDINAL VAGINAL SEPTUM



COMPLETE SEPTATE UTERUS WITH SEPTATE CERVIX AND LONGITUDINAL VAGINAL SEPTUM



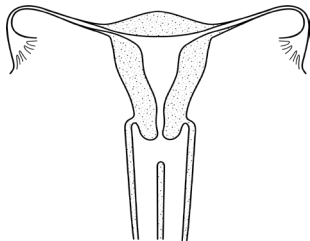
COMPLETE SEPTATE UTERUS, DUPLICATED CERVICES, AND OBSTRUCTED R/L HEMIVAGINA



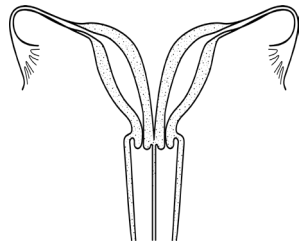
DISTAL VAGINAL AGENESIS

LONGITUDINAL VAGINAL SEPTUM

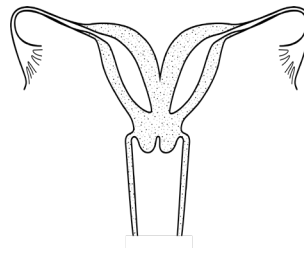
COMPLEX ANOMALIES



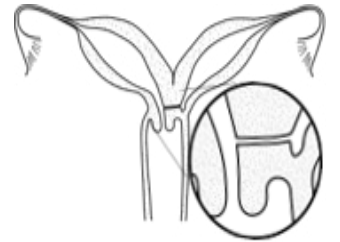
LONGITUDINAL VAGINAL SEPTUM OF VARIABLE LENGTH



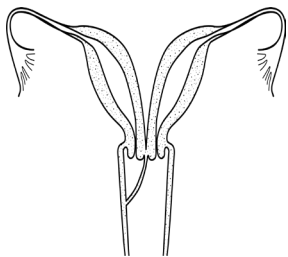
LONGITUDINAL VAGINAL SEPTUM OF VARIABLE LENGTH AND UTERUS DIDELPHYS



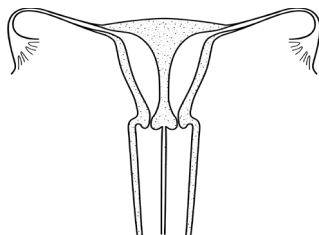
BICORNUATE UTERUS WITH BILATERAL OBSTRUCTED ENDOMETRIAL CAVITIES



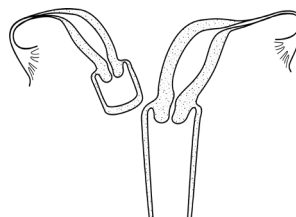
UTERUS DIDELPHYS WITH COMMUNICATING HEMIUTERI AND UNILATERAL R/L CERVICO-VAGINAL ATRESIA



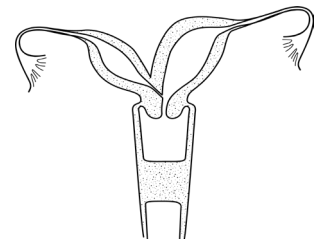
OBSTRUCTED R/L HEMIVAGINA AND UTERUS DIDELPHYS



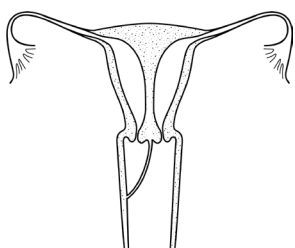
LONGITUDINAL VAGINAL SEPTUM OF VARIABLE LENGTH AND COMPLETE SEPTATE UTERUS WITH DUPLICATED CERVIX



OBSTRUCTED R/L HEMIVAGINA, HEMIUTERUS AND SINGLE CERVIX WITH SEPARATE CONTRALATERAL R/L PATENT HEMIUTERUS, CERVIX AND VAGINA



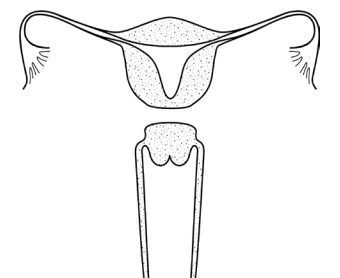
BICORNUATE UTERUS WITH R/L COMMUNICATING TRACT AND TRANSVERSE VAGINAL SEPTUM



OBSTRUCTED R/L HEMIVAGINA AND COMPLETE SEPTATE UTERUS WITH DUPLICATED CERVICES



Scan QR code to view the ASRM MAC 2021 tool (page 2 of 2)
©2021 American Society for Reproductive Medicine



UTERUS ISTHMUS AGENESIS